

One-stage Transalveolar versus Lateral Maxillary Sinus Augmentation in Severely Resorbed Sites using Calcium Phosphosilicate Putty: A Proof-Of-Concept Study

Udatta Kher¹ Siddharth Shanbhag^{1,2}

¹ Private Practice, Mumbai, India; ² Dept. of Periodontology, Faculty of Odontology, Malmö University, Sweden

Topic: Implant therapy outcomes, surgical aspects

Background and Aim

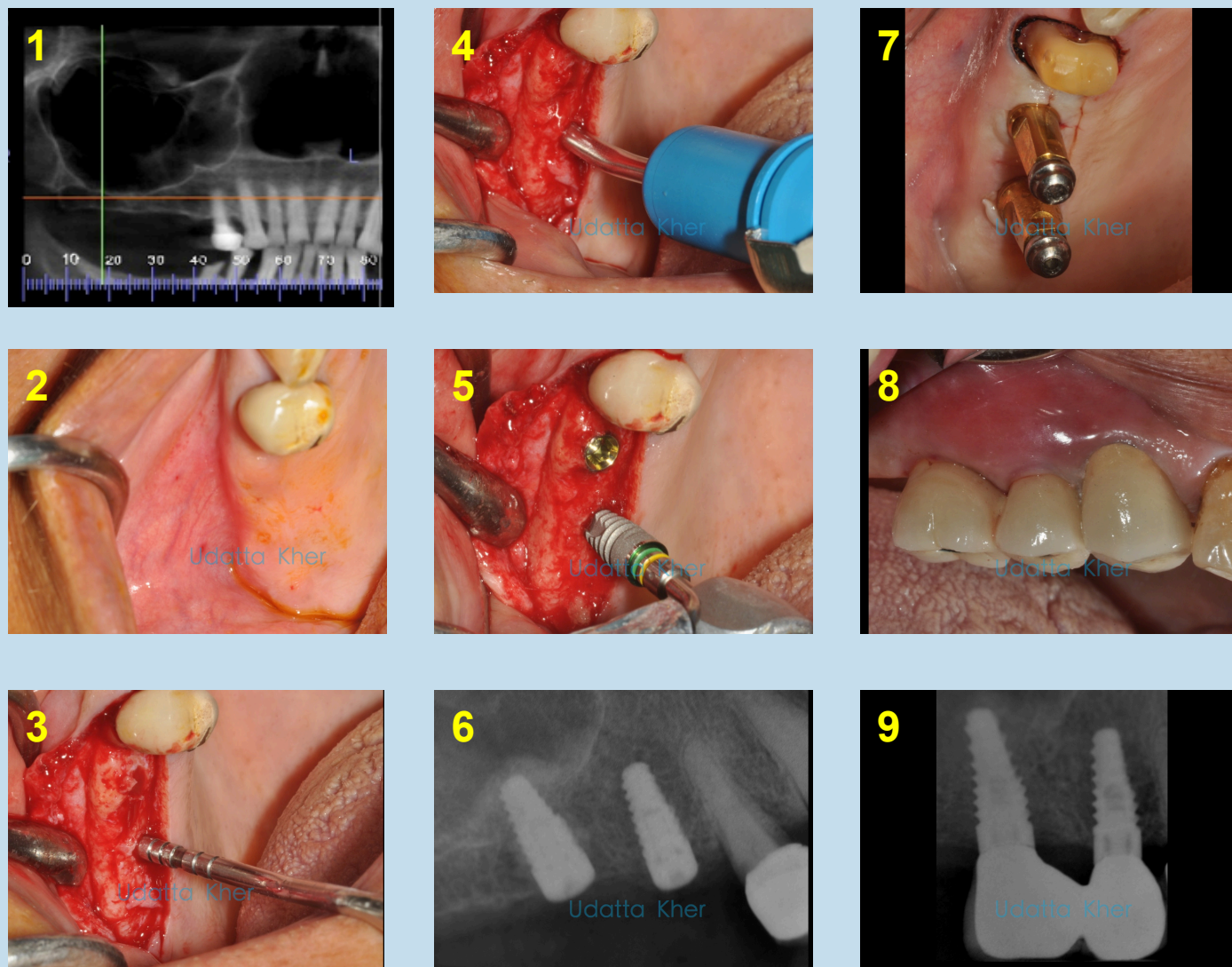
Benefits of simultaneous implant placement with lateral or transalveolar maxillary sinus floor augmentation (SFA) include reduced morbidity and shorter healing times¹. The decision to use a lateral or relatively less-invasive transalveolar approach is based on the residual ridge height (RRH > or < 5 mm) and likelihood of achieving adequate primary implant stability, which can ultimately predict implant success^{2, 3}. Bioactive glasses such as calcium phosphosilicate (CPS) are clinically well-studied alloplastic bone-substitutes for SFA. A technique for 1-stage transalveolar SFA and implant placement using an injectable CPS-putty in moderately resorbed sites (mean RRH 7 mm) has previously been reported⁴.

The aim of the present study was to compare the clinical and radiographic outcomes of transalveolar and lateral SFA using an injectable CPS-putty and simultaneous implant placement in severely resorbed sites (RRH ≤5 mm).

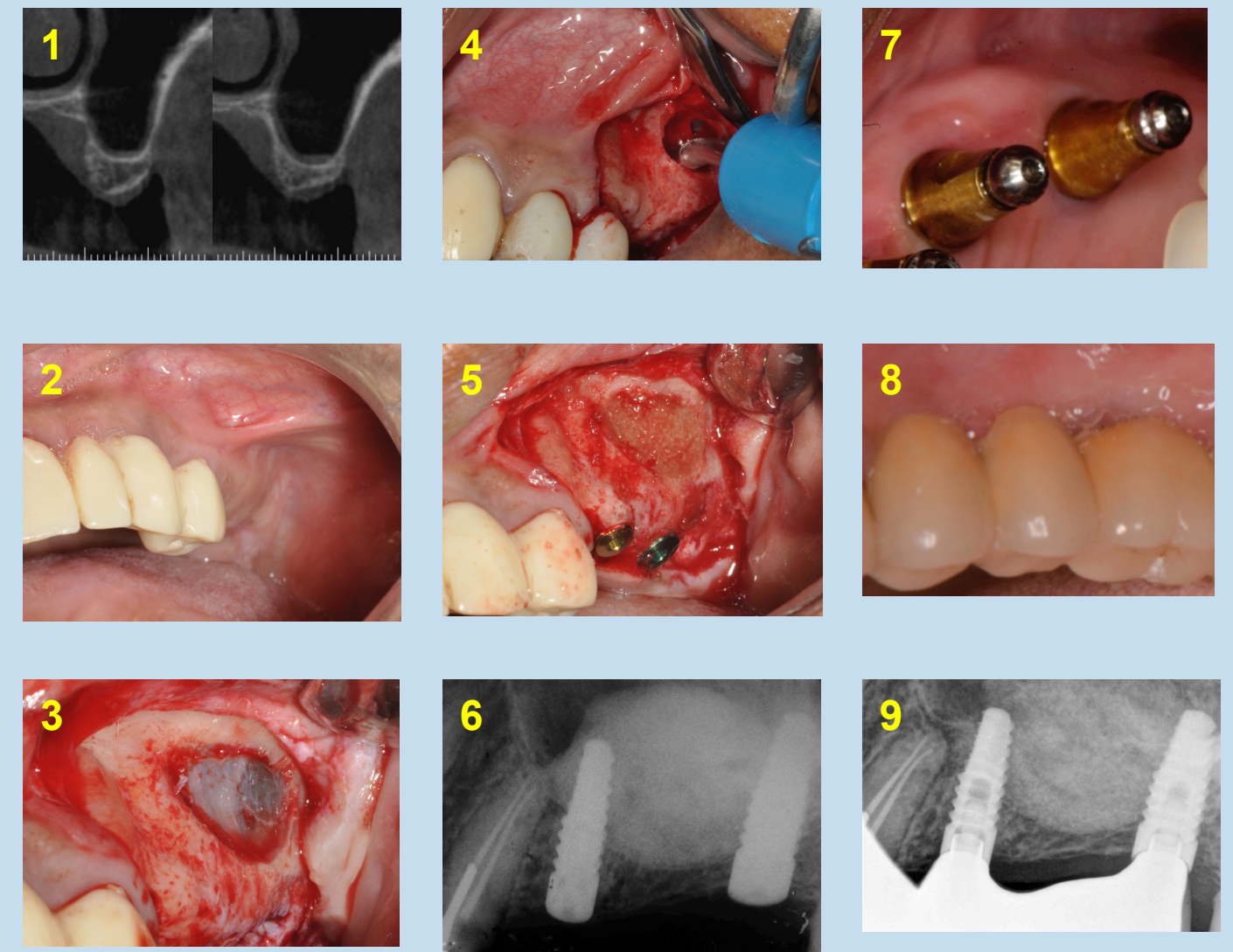
Methods

20 healthy non-smokers (11 females) aged 34–65 years with >1 missing posterior maxillary teeth and RRH ≤5 mm were included. Two groups of patients (10 per group) underwent SFA with **CPS-putty (NovaBone Dental Putty®)** either via a lateral or transalveolar approach along with simultaneous implant placement. In the transalveolar approach, osteotomies were first prepared within 1mm of the sinus floor, which was then fractured using an osteotome and 0.5cc of CPS-putty was injected via a cartridge delivery system resulting in hydrostatic membrane elevation. Totally, 28 implants were placed submerged; 15 in the lateral and 13 in the transalveolar group, all of 10.5 mm length. Average time to loading was 4 months. Radiographs taken at surgery and after ≥4 months were calibrated using implant length/diameter and compared independently by 2 examiners. Quantitative and qualitative graft changes were evaluated using linear measurements and the Sinus Graft Remodeling Index (SGRI), respectively. Means +/- SD and comparative statistics were analysed (p<0.05 significance).

Surgical Technique



Transalveolar approach: osteotomies were first prepared within 1mm of the sinus floor, which was then fractured using an osteotome and 0.5cc of CPS-putty was injected via a cartridge delivery system resulting in hydrostatic membrane elevation.



Lateral approach: the Schneiderian membrane was surgically elevated via an antrostomy and 1-1.5 cc of CPS-putty was injected into the sinus floor, prior to osteotomy preparation and implant placement. Intraoperative membrane perforation (Valsalva test) was assessed.

Results

Mean RRH was 4.35 ± 0.43 mm and 4.30 ± 1.30 mm in the lateral and transalveolar groups, respectively ($p > 0.05$). Adequate primary stability (>35 N-cm) was achieved for all implants. No incidences of membrane perforation and minimal postoperative pain were observed in both groups; although 'swelling' was reported more frequently after lateral SFA. In one patient in each group, one implant failed to osseointegrate. All other implants were loaded without biological or technical complications. After a mean follow up of 7.8 ± 3.3 months significant mean radiographic bone gains of 9.19 ± 2.16 mm and 9.86 ± 3.08 mm were observed within the lateral and transalveolar groups, respectively; with no significant differences between the groups. Radiographic appearance changed from 'original sinus floor lamina dura still recognizable' (SGRI score 1) to a 'new sinus floor outline' (SGRI score 3) in ~80% of cases in both groups; with ~1–2 mm of bone present apical to the implants in all cases.

Conclusion

This controlled proof-of-concept study confirms the clinical feasibility and effectiveness of using a minimally-invasive transalveolar approach with CPS-putty for 1-stage SFA and implant placement in alveolar sites with 3–5 mm of residual bone, which would otherwise be indicated for a more invasive lateral SFA approach.

References:

1. Fugazzotto PA. Maxillary sinus grafting with and without simultaneous implant placement: technical considerations and case reports. *Int J Periodontics Restorative Dent.* 1994 Dec;14(6):544–51.
2. Cha H-S, et al. Simultaneous sinus lift and implant installation: prospective study of consecutive two hundred seventeen sinus lift and four hundred sixty-two implants. *Clin Implant Dent Relat Res.* 2014 Jun;16(3):337–47.
3. Del Fabbro M, Wallace SS, Testori T. Long-term implant survival in the grafted maxillary sinus: a systematic review. *Int J Periodontics Restorative Dent.*;33(6):773–83.
4. Shanbhag S, Kher U. Minimally invasive transalveolar sinus floor elevation and implant placement using calcium phosphosilicate putty via a novel cartridge delivery system. *EAO Congress 2013; Poster abstract.*